

NEUROLOGY

Testosterone versus testosterone and testolactone in treating reproductive and sexual dysfunction in men with epilepsy and hypogonadism

Andrew G. Herzog, Pavel Klein and Alan R. Jacobs
Neurology 1998;50;782-784

This information is current as of January 7, 2010

The online version of this article, along with updated information and services, is located on the World Wide Web at:

<http://www.neurology.org/cgi/content/full/50/3/782>

Neurology® is the official journal of the American Academy of Neurology. Published continuously since 1951, it is now a weekly with 48 issues per year. Copyright © 1998 by AAN Enterprises, Inc. All rights reserved. Print ISSN: 0028-3878. Online ISSN: 1526-632X.



Testosterone versus testosterone and testolactone in treating reproductive and sexual dysfunction in men with epilepsy and hypogonadism

Article abstract—Antiepileptic drug-induced reductions in serum levels of biologically active testosterone and elevations in serum estradiol (E2) may contribute to sexual dysfunction among men with epilepsy. Treatment using a combination of testosterone and the aromatase inhibitor testolactone may have significantly better effects on sexual function and also seizure frequency than testosterone alone.

NEUROLOGY 1998;50:782-784

Andrew G. Herzog, MD; Pavel Klein, MD; and Alan R. Jacobs, MD

Reduced potency and hyposexuality occur in 38 to 71% of men with epilepsy.¹ Toone et al.² found that decreased sexual interest was associated with reductions in free testosterone. Fenwick et al.³ demonstrated a relationship between decreased potency and low free testosterone levels. Herzog et al.⁴ measured abnormally low, biologically active, i.e., non-sex hormone-binding globulin (SHBG)-bound (free plus albumin-bound), testosterone levels in five of eight treated epileptic men with diminished sexual interest or reduced potency. In a subsequent investigation, Herzog et al.⁵ observed that among 13 men with epilepsy, those who were classified as sexually normal had an almost twofold higher average non-SHBG-bound testosterone value than those with reproductive or sexual dysfunction (2.4 versus 1.4 ng/mL). Nevertheless, only three of eight hyposexual men had levels below the normal control range, and the average values of both groups were normal.

Another important endocrine factor may be estradiol elevation. Herzog et al.⁶ found total and non-SHBG-bound serum estradiol levels to be significantly higher among phenytoin-treated men with epilepsy than among untreated epileptic men or normal controls. A significant linear correlation between serum concentrations of biologically active estradiol and phenytoin, but not albumin or hepatic enzymes, suggests a direct medication effect rather than an indirect cause mediated via drug-induced hepatic dysfunction.⁷ The finding of elevated estradiol raises the possibility that enzyme-inducing antiseizure medications may lower biologically active testosterone not only by the induction of SHBG synthetase, but perhaps also by the induction of aromatase, which converts testosterone to estradiol. Estrogen lowers male sexual interest and function.⁸ Murialdo et al.⁹ demonstrated significantly higher serum estradiol levels and significantly lower free testosterone-to-estradiol ratios in hyposexual men with epilepsy than in either normosexual men with epilepsy or normal controls. Estradiol exerts a potent inhibitory influence on luteinizing hormone secretion and plays a

major role in negative feedback in men as well as women.⁹ Suppression of luteinizing hormone secretion results in hypogonadotropic hypogonadism. Chronically low free testosterone leads to testicular failure and hypergonadotropic hypogonadism. This may explain the frequent occurrence of both of these reproductive endocrine disorders in men with epilepsy.¹

Testosterone replacement is the most common form of therapy for hypogonadism. There are also some reports that ascribe anticonvulsant properties to testosterone when used in experimental animals.¹ This view, however, remains controversial. One possible explanation is that although one major testosterone metabolite, dihydrotestosterone, blocks *N*-methyl-D-aspartate transmission¹⁰ and may thereby have antiseizure effects, another metabolite, estradiol, increases seizure discharges.⁶ Because testosterone increases estradiol, which in turn counteracts favorable androgenic influences on reproductive function and epilepsy, inhibition of androgen conversion to estrogen is desirable and can be accomplished by the addition of an aromatase inhibitor. The effects of androgen therapy in men with epilepsy have not been reported. This investigation compared our past experience with the effects of treatment with testosterone¹ versus a subsequent trial of the combination of testosterone and the aromatase inhibitor testolactone on reproductive/sexual function and seizure frequency in antiepileptic drug-treated hyposexual men with refractory complex partial seizures and hypogonadism.

Methods. The subjects were 17 consecutive men with intractable complex partial seizures who had reproductive/sexual dysfunction in the setting of hypogonadism. Ages ranged between 34 and 51 years. All had clinically documented intractable complex partial seizures and paroxysmal epileptiform discharges unilaterally or bilaterally in temporal lobe derivatives on interictal EEG despite therapeutic-range serum levels of optimally effective enzyme-inducing antiseizure medications used alone or as polytherapy. The medications included carbamazepine, phenytoin, and barbiturates. All had complaints of reduced

Table Hormonal and clinical data before and during treatment

T group (n = 12)	BAT (ng/dL)	E2 (pg/mL)	S-score (1 to 20)	Sz freq (avg no./mo)
Before therapy	81.6 (±10.8)	42.7 (±10.2)	8.3 (±1.7)	4.4 (±2.2)
During therapy	327.8 (±35.1)	65.3 (±5.5)	11.0 (±1.6)	4.5 (±1.7)
<i>p</i> Value	<i>p</i> < 0.01	<i>p</i> < 0.01	<i>p</i> < 0.01	NS
T-TL group (n = 5)				
Before therapy	99.2 (±34.8)	43.4 (±13.0)	9.8 (±2.9)	17.0 (±12.7)
During therapy	277.2 (±108.7)	35.5 (±9.5)	17.8 (±1.3)	1.0 (±1.4)
<i>p</i> Value	<i>p</i> < 0.05	NS	<i>p</i> < 0.05	NS

T = Depo-Testosterone 400 mg IM every 2 weeks; T-TL = Depo-Testosterone 400 mg IM every 2 weeks + testolactone 3 to 500 mg/d; BAT = bioactive testosterone (normal, 125 to 350 ng/dL); E2 = estradiol (normal, 20 to 50 pg/mL); S-score = reproductive and sexual questionnaire score; Sz freq = seizure frequency.

sexual interest or potency and scores (s-scores) of less than 12 of 20 on a questionnaire of sexual and reproductive function that dealt with frequency of sexual thoughts and intercourse as well as success in maintaining erection and achieving orgasm. Baseline serum biologically active testosterone levels were abnormally low on at least two morning measurements (63 to 99 ng/mL; normal range, 125 to 350 ng/dL) in 16 of the 17 subjects. The remaining subject had complaints of both impotence and hyposexuality, with a level of 157 ng/mL. Baseline and treatment data were based on at least 3 months of follow-up with monthly determinations of gonadal steroid levels and s-scores.

Twelve were treated in 1990¹ with Depo-Testosterone (T) 400 mg IM biweekly to achieve normalization of serum bioactive testosterone levels. Five were treated in 1995 with the combination of Depo-Testosterone 400 mg IM biweekly in combination with the oral aromatase inhibitor testolactone 3 to 500 mg/d (T-TL). Early-morning gonadal steroid levels were measured before treatment and before injection during treatment. Testolactone dosage was adjusted to normalize abnormally elevated serum estradiol levels to the normal range of 20 to 50 pg/mL. Sexual interest and potency were assessed by questionnaire and scored on a scale of 1 to 20 (s-score).

Results. Hormonal data, s-scores, and seizure frequencies before and during treatment are presented in the table. Comparisons between treatment groups are presented in figure 1. The two groups did not differ significantly in age (T: median = 46, range = 34 to 50; T-TL: median = 50, range = 38 to 51). Bioactive testosterone levels were normalized in all cases with no difference between treatment groups. Estradiol levels, however, were significantly lower with T-TL than with T treatment (21 to 52 pg/mL versus 58 to 73 pg/mL; *p* < 0.001). S-scores improved three times more with T-TL than with T alone (8.0 versus 2.7; Mann-Whitney test *p* < 0.001). Improvement in s-scores did not correlate with changes in serum levels of bioactive testosterone but did show a statistically significant inverse correlation with serum estradiol (figure 2). T-TL was also associated with a greater reduction in seizure frequency (*p* = 0.03).

Discussion. Hypogonadism is a cause of reduced potency and hyposexuality in men with epilepsy.¹ Testosterone replacement is the most common form

of therapy for hypogonadism. The data in this investigation show that normalization of biologically active testosterone levels is associated with a statistically significant elevation in scores of sexual interest and function (see table). Combined treatment with testolactone, however, is associated with a

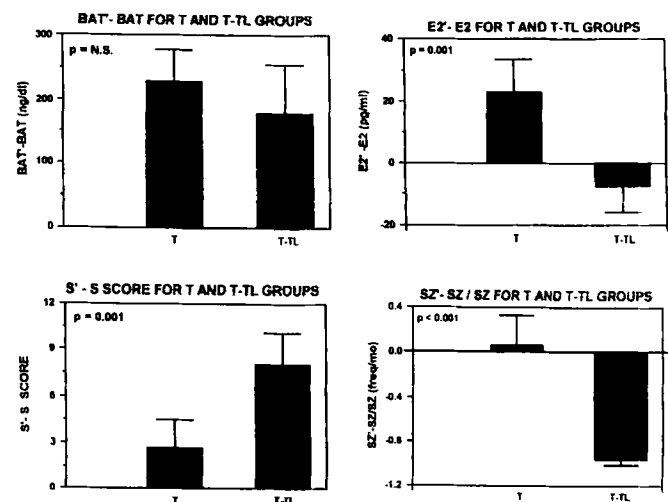


Figure 1. A comparison of hormonal and clinical changes between testosterone and testosterone-testolactone groups. T = testosterone; T-TL = testosterone plus testolactone; BAT = bioactive testosterone; E2 = estradiol; SZ = seizure; ' = on hormonal treatment.

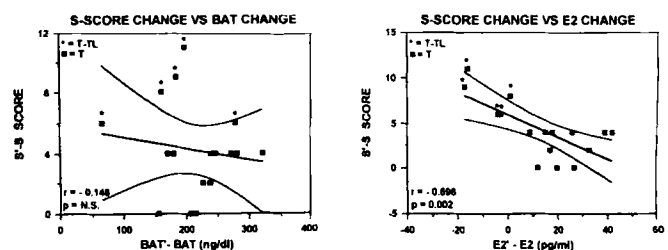


Figure 2. Relation between changes in sexual and reproductive questionnaire scores and changes in serum bioactive testosterone and estradiol levels before and during treatment. BAT = bioactive testosterone; E2 = estradiol; ' = on hormonal treatment.

significantly greater improvement despite similar changes in biologically active testosterone levels in the two groups. One possible explanation is that antiseizure medications that induce increased enzyme synthesis may enhance the conversion of endogenous and administered testosterone to estradiol by aromatase.⁶⁻⁸ Estradiol exerts a potent inhibitory influence on luteinizing hormone secretion⁹ and lowers male sexual interest and function.¹ Inhibition of androgen conversion to estrogen is successfully accomplished in this investigation by the aromatase inhibitor testolactone. The greater improvement with combined therapy and the statistically significant inverse correlation between changes in s-scores and serum estradiol suggest that normalization of estradiol as well as testosterone is associated with greater improvement in sexual function than normalization of testosterone alone. Because estradiol has epileptogenic effects,¹ the significantly greater reduction in serum estradiol using combined therapy may also be responsible for the significantly greater reduction in seizure frequency with combined therapy as compared with testosterone therapy alone.

From the Harvard Neuroendocrine Unit, Beth Israel Deaconess Medical Center, Boston, MA.

Presented in part at the 48th annual meeting of the American Academy of Neurology, San Francisco, CA, March 1996.

Received March 11, 1997. Accepted in final form August 19, 1997.

Address correspondence and reprint requests to Dr. Andrew G. Herzog, Harvard Neuroendocrine Unit, Beth Israel Deaconess Medical Center, 330 Brookline Avenue, Boston, MA 02215.

References

1. Herzog AG. Reproductive endocrine considerations and hormonal therapy for men with epilepsy. *Epilepsia* 1991;32(suppl 6):S34-S37.
2. Toone BK, Wheeler M, Nanjee M, et al. Sex hormones, sexual activity and plasma anticonvulsant levels in male epileptics. *J Neurol Neurosurg Psychiatry* 1983;46:824-826.
3. Fenwick PBC, Mercer C, Grant R, et al. Nocturnal penile tumescence and serum testosterone levels. *Arch Sex Behav* 1986;15:13-21.
4. Herzog AG, Seibel MM, Schomer DL, Vaitukaitis JL, Geschwind N. Reproductive endocrine disorders in men with partial seizures of temporal lobe origin. *Arch Neurol* 1986;43:347-350.
5. Herzog AG, Drislane FW, Schomer DL, et al. Abnormal pulsatile secretion of luteinizing hormone in men with epilepsy: relationship to laterality and nature of paroxysmal discharges. *Neurology* 1990;40:1557-1561.
6. Herzog AG, Levesque L, Drislane F, Ronthal M, Schomer D. Phenytoin-induced elevation of serum estradiol and reproductive dysfunction in men with epilepsy. *Epilepsia* 1991;32:550-553.
7. Herzog AG, Coleman AE. Serum estradiol correlates with phenytoin but not hepatic enzyme and albumin levels in men with epilepsy. *Epilepsia* 1994;35:52. Abstract.
8. Murialdo G, Galimberti CA, Fonzi S, et al. Sex hormones and pituitary function in male epileptic patients with altered or normal sexuality. *Epilepsia* 1995;36:358-363.
9. Winters S, Janick J, Loriaux L, Sherins R. Studies on the role of sex steroids in the feedback control of gonadotropin concentrations in men. II. Use of the estrogen antagonist clomiphene citrate. *J Clin Endocrinol Metab* 1979;48:222-227.
10. Pouliot WA, Handa RJ, Beck SG. Androgen modulates N-methyl-D-aspartate-mediated depolarization in CA1 hippocampal pyramidal cells. *Synapse* 1996;23:10-19.

Late-onset temporal lobe epilepsy and dilatation of the hippocampal sulcus by an enlarged Virchow-Robin space

Article abstract—MRI signal changes within the hippocampal sulcus have been attributed to a dilated Virchow-Robin space within that sulcus, but no clinical correlates have previously been described. We present a 64-year-old man who developed right temporal seizures. MRI revealed an unusually enlarged Virchow-Robin space within the hippocampus, suggesting space-occupying effect. Such an abnormality should be considered a possible etiology in patients with late-onset temporal lobe epilepsy.

NEUROLOGY 1998;50:784-787

A. Cunha Bastos, MD; F. Andermann, MD, FRCP(C); D. Melançon, MD, FRCP; F. Cendes, MD, PhD; A. Guberman, MD, FRCP(C); F. Dubeau, MD, FRCP(C); and A. Olivier, MD, FRCS(C)

Epilepsy beginning in adult life is not uncommon, and one-fourth of patients have their first seizure after the age of 25. In contrast to younger individuals, the etiology is more often a structural lesion. Cerebrovascular disease is considered a common cause in older patients, but in a large proportion of cases, the etiology remains unknown.^{1,2}

Among patients with late-onset epilepsy, complex partial seizures suggesting temporal lobe origin occur in approximately 14%, and the imaging studies are most often described as normal.²

We report a patient who developed complex and simple partial seizures of temporal lobe origin and complex partial status epilepticus at the age of 64 years. The MRI revealed an unusual dilated perivascular space within the hippocampus causing focal enlargement in the virtual cavity of the hippocampal sulcus. We discuss the likelihood of a causal relationship between this finding and the late onset of ipsilateral temporal lobe epilepsy.

Case report. A 64-year-old man had a first generalized tonic-clonic seizure followed by complex partial status epi-

Testosterone versus testosterone and testolactone in treating reproductive and sexual dysfunction in men with epilepsy and hypogonadism

Andrew G. Herzog, Pavel Klein and Alan R. Jacobs
Neurology 1998;50:782-784

This information is current as of January 7, 2010

Updated Information & Services	including high-resolution figures, can be found at: http://www.neurology.org/cgi/content/full/50/3/782
Permissions & Licensing	Information about reproducing this article in parts (figures, tables) or in its entirety can be found online at: http://www.neurology.org/misc/Permissions.shtml
Reprints	Information about ordering reprints can be found online: http://www.neurology.org/misc/reprints.shtml

